

XANTHOGRANULOMATOUS PYELONEPHRITIS- A CASE SERIES

Received : 08/01/2024
 Received in revised form : 20/03/2024
 Accepted : 05/04/2024

Keywords:
Xanthogranulomatous, pyelonephritis, nephrectomy, transplantation.

Corresponding Author:
Dr. Vinaya B Shah,
 Email: vinayabshah@gmail.com

DOI: 10.47009/jamp.2024.6.2.143

Source of Support: Nil,
 Conflict of Interest: None declared

Int J Acad Med Pharm
 2024; 6 (2); 682-685



Sneha P Janjal¹, Vinaya B Shah², Anupama S.N³, Siddhi Shah⁴

¹Assistant Professor, Department of Pathology, H.B.T Medical College and Dr. R. N Cooper hospital, Mumbai, India

²Additional Professor, Department of Pathology, H.B.T Medical College and Dr. R. N Cooper hospital, Mumbai, India

³Junior Resident, Department of Pathology, H.B.T Medical College and Dr. R. N Cooper hospital, Mumbai, India

⁴Ex- Intern, H.B.T Medical College and Dr. R. N Cooper hospital, Mumbai, India

Abstract

Background: To study clinical and histopathological features of Xanthogranulomatous Pyelonephritis (XPN) over a period of ten years. **Materials and Methods:** This study was conducted in tertiary municipal health care system and consisted of 19 cases from consecutive 10 years. We received total nephrectomy specimens. Clinical details were obtained from the medical records. Histopathological examination was done from the received specimens. Special stains were performed as and when required. **Result:** Males were affected more than females. The most common symptom was flank pain, fever with chills and rigors, pain in abdomen. Eleven cases showed presence of calculi. Right kidney was affected more than left. **Conclusion:** A non-neoplastic lesion like XPN can make a kidney completely non-functional. The symptoms are trivial to start with. Early diagnosis and prompt treatment can help in salvaging the kidney and prevent the need for transplantation.

INTRODUCTION

Xanthogranulomatous pyelonephritis (XPN) is a rare chronic granulomatous pathology of kidney characterized by replacement of normal renal parenchyma by lipid laden macrophages which results in severe loss of function. Schlagenhauser had first mentioned XPN in 1916 and it is rightly described by the Greek name which stands for “Xantho” meaning yellow and “Pyelonephritis” meaning inflammation of pelvis and kidney.^[1,2]

The incidence of XPN varies from 0.6% to 1% of all cases of pyelonephritis.^[1,3] It affects the female population more than males.^[1,4] Age is not a barrier to XPN and cases are seen in pediatric and geriatric patients as well.^[2,4] The symptoms are usually mild to begin with and consists of urinary tract infection (UTI), fever (on and off), weight loss, flank pain etc.^[4] This is a slow continuous process and keeps on deteriorating the kidney function ultimately causing non-functional kidney. Radiological appearance is quite interesting as it's presentation simulates with malignancy, hence it is aptly called as “great imitator”.^[5,6]

How a non-neoplastic inflammatory lesion renders a kidney non-functional is a matter of quest and concern to the treating nephrologist, radiologist and pathologist as well. Hereby we present a case series

of 19 cases of XPN which highlight some of the important issues.

MATERIALS AND METHODS

This is a retrospective observational study conducted in a tertiary municipal health care system. The study comprises total 19 cases from the consecutive 10 years. Clinical details were retrieved from the medical records. Appropriate measures were taken to publish the data without revealing patient identities. All the patients underwent the surgical procedure of total nephrectomy. The specimens were received from the surgical department and were immediately fixed in 10% neutral buffered formalin. After 24 hours of fixation, paraffin wax embedding, thin sections of 5 µm were obtained. These sections were stained with routine Haematoxylin and Eosin stain. Special stains for acid fast bacilli (AFB), PAS (Periodic Acid Schiff) and fungi were performed in some circumstances to rule out other etiologies.

RESULTS

This study consisted of ten males and nine female patients. The youngest patient was two and half years old female and the oldest patient was a 64 years old male. The male to female ratio was 1.1:1.

The most common symptom observed was flank pain, fever with chills and rigors, pain in abdomen. Also, one patient came with a flank mass. Computed Tomography (CT) scan done in one patient revealed renocolic fistula. Also, some of the patients presented with renal abscess, pyonephrosis and hydronephrosis. Thus, a wide spectrum of presentation was noted.

Non-functioning kidney was found in 6 cases (32 %). Eleven cases (58 %) showed presence of calculi. The shortest duration of presentation was one month and the longest duration was three years. The most common duration of symptoms was six months.

Urine reports and other laboratory parameters were not available for assessment. It was observed that right kidney (n=12, 63%) was affected more than left (n=7, 37%).

Gross:

We received unilateral nephrectomy specimens in all the cases and the kidneys were significantly enlarged. Five cases showed pyonephrosis and two cases showed hydronephrosis. One of the specimens showed flea bitten appearance. The capsule was thickened and adherent to the underlying tissue with bosselated surface. There was increase in perinephric fat. On cut opening, there was complete loss of normal renal parenchyma with no cortico-medullary demarcation. Cortex showed multiple yellowish firm nodules measuring 0.5 to 1 cm with central necrotic haemorrhagic focus.

The pelvicalyceal system was dilated with irregular surface. In cases where obstruction was the etiological factor, calculus was found. At places, extensive fibrosis and scarring was seen. Our series, included a renal transplant recipient. In this case, the transplant kidney was not affected and patient remained healthy after total nephrectomy.

Microscopy:

Microscopic examination of all cases revealed a spectrum of histopathological features. In all the cases the glomeruli were reduced markedly and showed sclerosis and periglomerular fibrosis. The tubules were atrophic and showed thyroidisation. Dense inflammatory exudate in peripelvic fatty tissue, marked collagenisation was seen giving a storiform pattern. The surrounding blood vessels were thickened.

The pelvicalyceal epithelium was ulcerated with similar dense inflammation underneath. Foci of abscesses seen. Collection of lipid laden macrophages which is the hallmark of XPN was seen in all the cases.

These collections were surrounded by dense lympho-plasmacytic inflammatory infiltrate and giant cells.

However, no frank granulomas were identified and these were confirmed by negative AFB stain. Few cases showed pus casts in the distal tubules. Cholesterol clefts were also seen.

A pediatric case (age two and half years) was also taken into consideration. Post chemotherapy nephrectomy specimen was received. Microscopy

showed scanty remnants of Wilm's tumor (neoplastic tubules along with stroma) in the background of XPN.

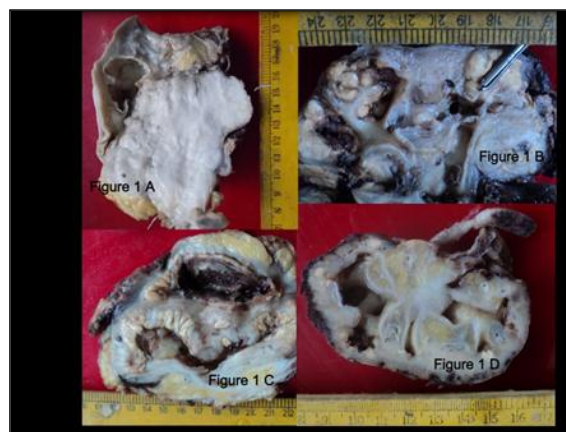

Figure 1: Showing gross features of XPN, note the loss of normal renal parenchyma

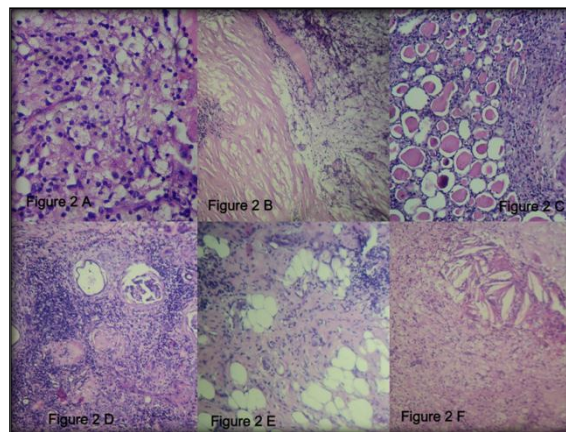


Figure 2: Microphotographs of XPN, A) Characteristic lipid laden macrophages, B) Perirenal fibrosis, C) Thyroidisation of tubules, D) Periglomerular fibrosis and thick walled blood vessels, E) Extension into adjacent adipose tissue, F) Cholesterol clefts

DISCUSSION

In our study males (n=19, 53%) were slightly affected more than females (n=9, 47%). This is mainly due to random distribution of patients within a span of ten years and seems to happen by chance. Abbas F et al, R. Loffroy et al and Razvan- Cosmin Petca et al have found that middle aged females are affected more than males.^[7-9]

Right kidney (n=12, 63%) was affected more than left kidney (n=7, 37%) which is similar to a study by Herrera-Bedoya et al and Ramos et al.^[10,11] However, Krishna et al and another study of 1000 cases found the opposite where the left kidney was affected more than right kidney.^[12,13]

Bilateral XPN is rare but can be severe and at times can be fatal.^[8,11] In our study only one kidney was involved.

Calculus was found in 11 cases (58%). Existing literature has stated a significant correlation between calculus and XPN. Nawaz et al found 100 %

correlation between calculus and XPN. Studies conducted by Laishram et al and Kundu et al also found association between calculi and XPN.^[12]

The main pathology behind XPN is obstruction and UTI.^[14,15] Most commonly found staghorn calculi results in obstruction and urinary stasis. Persistent stasis is a predisposing factor to UTI. In addition this UTI is usually caused by a low virulence microorganism like *E. coli*, *Proteus* etc, so the symptoms are mostly neglected and the inflammation never subsides.^[10,14] It is possible to detect UTI and the causative agent through urine culture but many times the urine is sterile. The reports are not conclusive since most of the patients are already started on antibiotics, so early diagnosis and treatment is difficult.^[13]

The mechanism behind XPN is the inability of the host macrophages to eliminate the bacterial infection with eventual formation of granuloma.^[5,10,15] In the past Anhalt et al described the underlying pathology where the infection incites the inflammatory response. Also, he also mentioned altered lipid metabolism, inadequate vascularity and obstruction are the additive factors.^[14,17]

The pain of XPN is dull aching as compared to renal colicky pain, hence not paid much attention.^[9] This is another reason for uninterrupted damage of kidney. Most of the times patients present with abscess, fistula and conditions where there is extensive involvement of perinephric tissues and organs.^[1,15] So, it is very difficult to salvage the kidney and it necessitates total nephrectomy. In our study, five patients (26 %) had pyonephrosis and two patients (11 %) had hydronephrosis.

Bolger et al has described some other precipitating factors which further accelerate the disease process, they are namely, pelvi-ureteric junction obstruction, parasitic infestation (*Schistosomiasis*), tumors, congenital anomalies and vesicoureteric reflux especially in children.^[2,5,15] In our study, we did not find any associated comorbidity. Comorbidities like DM, immune-incompetence and certain autoimmune disorders accentuate the symptoms. At times the associated weight loss and cachexia may lead to a wrong diagnosis of carcinoma.^[15] Thus, the symptoms of XPN are quite variable and often misleading.

Radiology can provide some insight for early diagnosis. There is no particular telltale sign of XPN but a constellation of signs and alertness can surely pinpoint XPN. CT scan findings are considered to be diagnostic to some extent. An enlarged kidney with the "bear paw" sign, calculus, dilated, expanded calices and extension of the lesion in the adjacent soft tissue/organ can confirm XPN.^[4,6,15]

Apart from XPN, xanthogranulomatous change is commonly seen in gall bladder, female genital tract (endometrium, ovaries, fallopian tubes), appendix and soft tissue.^[12,16] Even on histopathology, there are few differential diagnoses that need to be ruled out like malakoplakia, megalocytic interstitial nephritis and renal cell carcinoma (RCC).^[4,10,15]

Malakoplakia has the characteristic Michaelis-Gutmann bodies. Use of immunohistochemistry (IHC) is useful to differentiate XPN from RCC as XPN stains positive for CD68 whereas RCC stains positive for CD10.^[4,5,15] Our youngest patient was a two and a half years old female who was a case of Wilm's tumor (post chemotherapy). In this case we found scanty atrophic tubules and stroma surrounded by xanthogranulomatous change.^[4]

XPN is also a known complication in transplant cases. Immunosuppression which happens to be a part of treatment is an important predisposing factor for post-transplant infections and results in rejection. The risk is highest in first six months.^[18] Pelle et al and Giral et al found that post-transplant pyelonephritis is a risk factor for graft survival and may result in graft rejection.^[19,20]

In our series, XPN was not found in the transplanted kidney but in the other kidney. The patient was alright after surgery.

CONCLUSION

Even though XPN is a benign condition, early diagnosis is very important as it warrants total nephrectomy. The clues to the diagnosis are very subtle and bound to be missed. If diagnosed early, there is a possibility for conservative management instead of a total nephrectomy. Presence of calculus, female gender, dilated calyces, abscesses, fistula and involvement of adjacent soft tissues should always raise the suspicion of XPN. Clinical correlation, imaging findings and accurate judgement can prevent surgery. Prompt and complete treatment for UTI is recommended. All precautions must be taken while dealing with immunosuppression and metabolic diseases like diabetes mellitus.

REFERENCES

1. Çaliskan S, Özsoy E, Kaba S, Koca O, Öztürk MI. Xanthogranulomatous Pyelonephritis. Arch Iran Med. 2016 Oct;19(10):712-714.
2. Al-Saleem, Ilham Abd Allah. (2018). Some histopathological and biochemical changes in patients with chronic pyelonephritis. Journal of Pharmaceutical Sciences and Research. 10. 2808-2813.
3. Parmar, Himani & Patel, Mahesh & Parikh, Urvi & Goswami, Hansa. (2020). A clinicopathological study of Xanthogranulomatous pyelonephritis. International Journal of Clinical and Diagnostic Pathology. 3. 10-12. 10.33545/pathol.2020.v3.i3a.252.
4. Li L, Parwani AV. Xanthogranulomatous pyelonephritis. Arch Pathol Lab Med. 2011 May;135(5):671-4.
5. Veličković, Filip & Vljaković, Marina & Stevic, Milos & Veličković, Sanja & Veličković, Ljubinka. (2023). Xanthogranulomatous pyelonephritis and diagnostic approach: A case report. Acta Medica Medianae. 62. 75-80. 10.5633/amm.2023.0311.
6. Sharma, Sanjiv et al. "Ureteral involvement in xanthogranulomatous pyelonephritis- Rare manifestation." Indian Journal of Radiology and Imaging 16 (2006): 243 - 245.
7. Abbas, Farhat et al. "Clinicopathologic Spectrum of Xanthogranulomatous Pyelonephritis: A Single Center Experience over 8 Years." Journal of Renal and Hepatic Disorders (2022): n. pag.

8. Loffroy R, Guiu B, Watfa J, Michel F, Cercueil JP, Krausé D. Xanthogranulomatous pyelonephritis in adults: clinical and radiological findings in diffuse and focal forms. *Clin Radiol.* 2007 Sep;62(9):884-90. doi: 10.1016/j.crad.2007.04.008. Epub 2007 Jun 29.
9. Petca, Răzvan C.; Popescu, Răzvan I.; Mareş, Cristian; Mehedintu, Claudia; Mastalier, Bogdan; Badiu, Dumitru Cristinel; Măru, Nicoleta; Constantin, Vlad D.; and Petca, Aida (2019) "Xanthogranulomatous pyelonephritis: presentation and management," *Journal of Mind and Medical Sciences: Vol. 6: Iss. 1, Article 26.*
10. Herrera-Bedoya M, Avendaño-Capriles CA, Zakzuk-Martinez E, Barrera J. Xanthogranulomatous Pyelonephritis and Its Differential Diagnoses: An In-Depth Case Review. *Cureus.* 2021 Oct 29;13(10):e19133.
11. Lya Duarte Ramos, Marinus de Moraes Lima, Maurício de Carvalho, Geraldo Bezerra da Silva Júnior, Elizabeth de Francesco Daher, Emphysematous and xanthogranulomatous pyelonephritis: rare diagnosis, *The Brazilian Journal of Infectious Diseases*, Volume 14, Issue 4, 2010, Pages 374-376, ISSN 1413-8670.
12. Krishna M, Dayal S. Xanthogranulomatous inflammatory lesion mimicker of malignancy: A clinicopathological study from rural India. *North Clin Istanb.* 2021 Oct 6;8(5):485-492.
13. Harley F, Wei G, O'Callaghan M, Wong LM, Hennessey D, Kinnear N. Xanthogranulomatous pyelonephritis: a systematic review of treatment and mortality in more than 1000 cases. *BJU Int.* 2023 Apr;131(4):395-407. doi: 10.1111/bju.15878. Epub 2022 Sep 26. PMID: 35993745.
14. Gupta S, Araya CE, Dharmidharka VR. Xanthogranulomatous pyelonephritis in pediatric patients: case report and review of literature. *J Pediatr Urol.* 2010 Aug;6(4):355-8.
15. Bolger MP, Hennebry J, Byrne C, Greene L, Stroiescu A, Heneghan J, Ryan AG. Xanthogranulomatous Pyelonephritis: A Narrative Review with Current Perspectives on Diagnostic Imaging and Management, Including Interventional Radiology Techniques. *Int J Nephrol Renovasc Dis.* 2021 Sep 7;14:359-369.
16. Karthik, Dr. S. et al. "Clinicopathological Study of Xanthogranulomatous Inflammation." (2019).
17. Anhalt MA, Cawood CD, Scott Jr R. Xanthogranulomatous pyelonephritis: a comprehensive review with report of 4 additional cases. *J Urol* 1971; 105: 10-7.
18. Graversen ME, Dalgaard LS, Jensen-Fangel S, Jespersen B, Østergaard L, Søgaaard OS. Risk and outcome of pyelonephritis among renal transplant recipients. *BMC Infect Dis.* 2016 Jun 10;16:264.
19. Pellé G, Vimont S, Levy PP, Hertig A, Ouali N, Chassin C, Arlet G, Rondeau E, Vandewalle A. Acute pyelonephritis represents a risk factor impairing long-term kidney graft function. *Am J Transplant.* 2007 Apr;7(4):899-907.
20. Giral M, Pascuariello G, Karam G, Hourmant M, Cantarovich D, Dantal J, Blanco G, Coupel S, Josien R, Daguin P, Méchineau S, Soullillou JP. Acute graft pyelonephritis and long-term kidney allograft outcome. *Kidney Int.* 2002 May;61(5):1880-6.